



SKIN CANCER AND
RECONSTRUCTIVE SURGERY
CENTER

180 Newport Center Drive, Suite 158 | Newport Beach, CA 92660

949.719.1800

the Skin Cancer Connection

Publication of SCARS Center, Newport Beach

Spring 2019 • Volume IV

WELCOME MOHS SPECIALIST DR. ALEXANDER MILLER



Dr. Alexander Miller is now performing Mohs surgery at the SCARS Center in Newport Beach, alongside our team of specialists dedicated to the management of skin cancers. **As Dr. Miller embarks on a four-year term on the Board of Directors of the American Academy of Dermatology, he brings decades of surgical experience to the Skin Cancer and Reconstructive Surgery Center.**

Dr. Miller co-directs the annual American Society for Mohs Surgery Meeting on Skin Cancer, and a Skin Cancer Closure Course. He pens the popular monthly "Cracking the Code" column in *Dermatology World*, the most-read feature of that journal. He is a Clinical Professor of Dermatology at UC Irvine. We welcome his knowledge, expertise, and leadership to our practice.

Catch Dr. Miller at our monthly CME Conference to learn state-of-the-art skin cancer management, dermatopathology, or even coding.

INSIDE THIS ISSUE

Atypical Nevus Biopsy —
Leaving Involved Margins 2

Pediatric Office
Procedures with
Pro-Nox Nitrous Oxide 2

New Technology for
Sentinel Lymph Node
Biopsy for Melanoma 3

An Often Forgotten
Function of 5-Fluorouracil 3

SCARS Foundation
Information 4

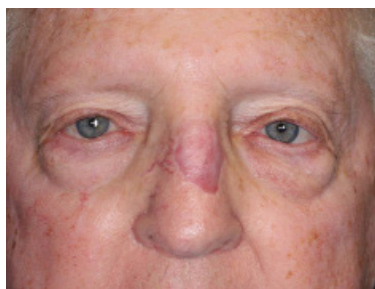SCARS CENTER SIGNATURE FLAPS

This patient presented for scar revision after excision of BCC of the nose performed elsewhere. The atrophic erythematous skin graft scar measured 3 x 2.6 cm and was excised. **The defect was reconstructed with two signature flaps of the SCARS Center, developed by Simon Madorsky, M.D. These flaps permit a single stage reconstruction of nasal defects traditionally treated with multistage regional flaps such as a forehead flap.** The lateral extended nasal island flap (LENI flap) was advanced 1.8 cm medially to close the inferior portion of the defect. The superior extended nasal myocuta-

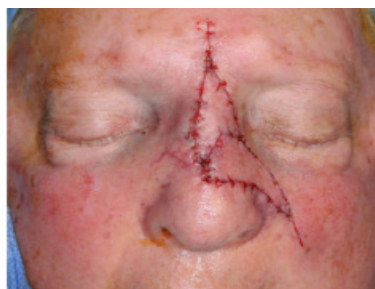neous island flap (SENMI flap) was advanced 1.5 cm to close the remainder of the defect.

Skin grafts can be a practical technique for skin defect reconstruction. They minimize incisions in the defect area, and avoid bruising and swelling of flap repairs. However, they have a tendency for contour depression and color mismatch. Skin grafts are best used for defects less than 1 cm. In our center, they are used mostly in combination with flaps or for small shallow defects.

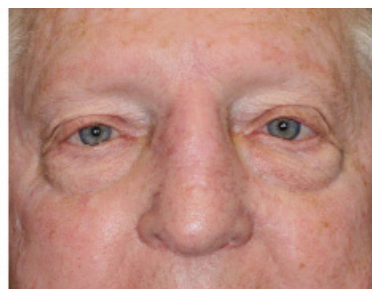To see detailed pictures of the technique, go to SCARSCenter.com > Physician Resources > Patient Case Studies.



Skin graft scar



Reconstruction performed with two signature flaps



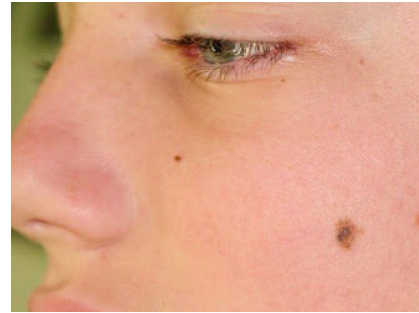Aesthetic outcome 4 months post-op

ATYPICAL NEVUS BIOPSY — LEAVING INVOLVED MARGINS

A 27-year-old woman presented with a recently changing left cheek nevus. Shave biopsy showed a nevus with moderate atypical melanocytic hyperplasia. Residual pigmentation of the nevus and involved histologic margins remained after the biopsy.

Are all atypical melanocytic lesions pre-melanomas? Should dysplastic lesions be promptly excised to avoid development of melanoma? Signs of melanoma and melanoma risks have been broadly publicized in the media and are widely known by the public. **The increased anxiety over melanoma risks has translated into more frequent biopsies and more aggressive surgical management. But a new multi-institutional study dispels that notion, at least for atypical nevi.**

These dysplastic moles have been treated aggressively with a 2 mm margin excision. New data supports observation of the previously biopsied moles instead of excision. The study published in *JAMA Dermatology* in October 2018 addressed moderately atypical



Atypical nevus with residual pigmentation before biopsy.

lesions. The retrospective study of previously biopsied dysplastic nevi found that none of them transformed into a melanoma over an average of 7 years.

The fact remains that patients with dysplastic nevi are at an increased lifetime risk of melanoma. However, melanoma anxiety should not focus on the lesions confirmed as atypical. Instead of chasing each atypical mole with complete excision, the patient's entire skin needs to be regularly examined. Conclusion? Less scars by surgeons and more self exams by patients.

PEDIATRIC OFFICE PROCEDURES WITH PRO-NOX™ NITROUS OXIDE

CASE STUDIES

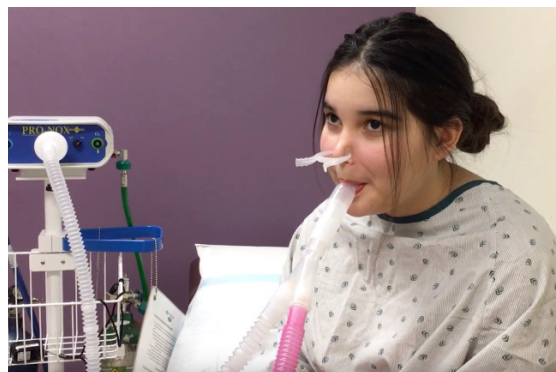The **Skin Cancer Connection** features summaries of cases presented at our monthly conference.

For more details on each article go to:

SCARSCENTER.COM

PHYSICIAN RESOURCES

PATIENT CASE STUDIES

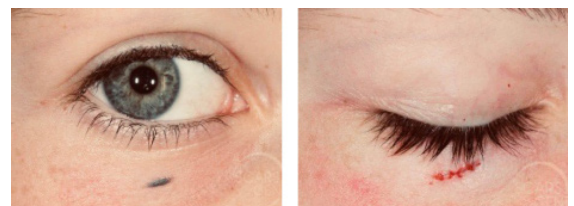

Graphic of a young patient using Pro-Nox™. This is not the patient referenced in this article.

Pediatric patients present a challenge for dermatologists and plastic surgeons when office surgical treatment is required. Unlike adults, children often require the operating room with anesthesia sedation when a simple excision is required. Office-administered nitrous oxide is changing that. Pro-Nox™ nitrous oxide system is bringing analgesia and light sedation into the office setting. The machine is simply a control valve that mixes oxygen with nitrous oxide as a 50:50 mixture. The flow is dependent upon the patient's inhalation effort, while providing no passive flow. This eliminates the need for gas

scavenging systems in the office. The patient-controlled sedation avoids over-sedation or loss of protective reflexes and eliminates the need for monitoring. Pediatric procedures become more tolerated in the office setting.

The treatment involves having the patient take 3 deep breaths while sucking on the Pro-Nox™ tubing. The effect is felt after 3 breaths. In many patients, 5 breaths are required for the desired result. Holding the breath at the peak of inhalation maximizes nitrous oxide absorption. Repeat inhalations may be required after 3 minutes as the effect wears off quickly. Our adult patients can drive 30 minutes after the last inhalation. In some patients, more than 5 breaths may cause brief nausea. Our patients have found this to be an important aid for anxiety and discomfort. Pro-Nox™ has expanded the possibilities of office procedures under local anesthesia.



Blue nevus in an 8 year old excised with use of Pro-Nox™.

NEW TECHNOLOGY FOR SENTINEL LYMPH NODE BIOPSY FOR MELANOMA

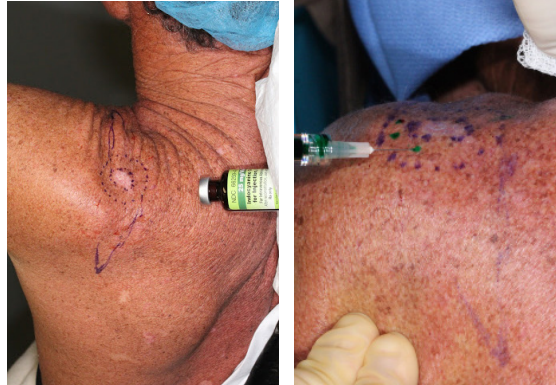This patient presented with a left shoulder malignant melanoma invading to 1.2 mm depth. The melanoma was excised, and a left axillary sentinel lymph node was biopsied. Near infrared laser lymphangiography with indocyanine green was used.

Sentinel lymph node biopsy can be a minimally invasive surgical procedure but not always. The radiotracer guided identification with a handheld gamma probe can easily identify the lymph node. Auditory feedback from this “Geiger counter” suggests proximity to the radiotracer containing lymph node. However, in some cases the deeper lymph nodes are harder to find and require a greater amount of surgical dissection. Methylene blue dye is an adjunct used to help with direct visual identification. Like the radiotracer, it is injected in the skin around the primary cancer site and is then visualized in the sentinel lymph node. It serves as confirmatory evidence of the sentinel lymph node, while the gamma probe is the primary detector of it.

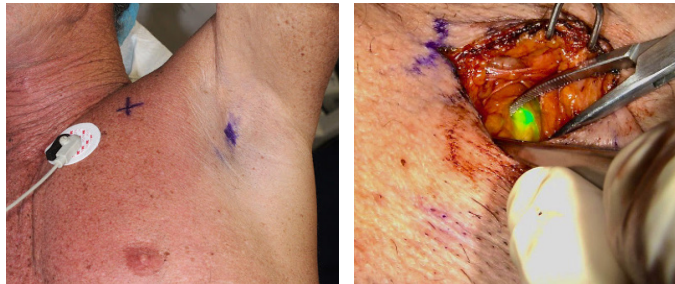
Near-infrared laser (NIL) lymphangiography with indocyanine green (ICG) fills the technological void between gamma probe detection and direct visual identification of the methylene blue dye. It visualizes the ICG containing lymph node 5-10 mm through surrounding tissue. It has been shown to increase the precision of lymph node detection. This spectrum of technologies is analogous to the self-driving car’s obstacle detection. These cars have the proximity ultrasonic detectors for up to 8 m, cameras

for mid distance, and radars for far distance. Similarly, methylene blue is the proximity detector, ICG guided NIL lymphangiography is the mid distance camera, while the gamma probe is the far distance radar.

Combining existing gamma probe technology, methylene blue visualization, with the ICG guided near infrared lymphangiography shortens the operative time, limits the surgical dissection, and increases the precision of lymph node detection.



Left shoulder melanoma injected with indocyanine green.



Left axilla with identified radiotracer location of the sentinel lymph node.

Lymph node identified with indocyanine.

REFER A PATIENT

To refer a patient or for more information about the Skin Cancer and Reconstructive Surgery Center, contact us:

949.719.1800

info@scarscenter.com

AN OFTEN FORGOTTEN FUNCTION OF 5-FLUOROURACIL



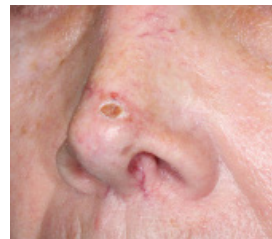This patient developed a second recurrence of basal cell carcinoma of the nasal tip. She had undergone 2 treatments with radiation therapy over the last 13 years, and did not want surgery.

There is only one nonsurgical alternative for treatment of deeply invasive basal cell carcinoma

that is not radiation. Intralesional chemotherapy is a rarely employed treatment that actually works. Although 5-fluorouracil is the most common intralesional chemotherapeutic option for basal cell carcinoma, many other agents have been shown to be as effective. They include bleomycin and various interferon

subgroups. For squamous cell carcinomas, intralesional methotrexate has also been shown to be effective.

The 5-fluorouracil treatment regimens vary from 1 to 3 times per week lasting 2-8 weeks. The dose of 5-FU (50 mg/ml concentration) ranges from 10-150 mg per injection. The median dose is approximately 50 mg (1cc). The results are impressive with cure rates in the high 90th percentile. What makes this treatment unproven is the limited follow up of these studies of 2 years or less.





SKIN CANCER AND
RECONSTRUCTIVE SURGERY
CENTER

180 Newport Center Drive, Suite 158
Newport Beach, CA 92660

POSTAGE
INDICIA
HERE

Address Block Will
Be Printed in this Area

UPCOMING SCARS FOUNDATION MONTHLY SKIN CANCER CONFERENCE DATES:

JUNE 18
JULY 16

AUGUST 20
SEPTEMBER 17

RSVP Online at SCARSCenter.com > Monthly Conference

*The Skin Cancer Connection
and SCARSCenter.com are
your source for diagnostic
dilemmas, treatment challenges,
and reconstructive issues for
challenging skin cancer cases.*



949.719.1800
info@scarscenter.com

EDUCATION. RESEARCH. SERVICE.

The Skin Cancer And Reconstructive Surgery (SCARS) Foundation offers specialized educational opportunities to the medical and scientific community who strive to achieve new knowledge in skin cancer management.

ACCREDITED ACTIVITY

The Continued Medical Education (CME) program we offer has been established as a high quality, evidence based CME program that is independent, fair, objective, relevant, and consists of prominent physicians representing various subspecialties including Head and Neck Surgical Oncology, Mohs Dermatology, Dermatopathology, Radiation Oncology, Medical Oncology, ENT, and Facial Reconstructive Surgery.

Each CME activity will be evaluated to see measure the program's impact on our learners to see if our expected results have been met, including pre and post activity surveys and tests, and self reporting changes in practice by physicians.